

Efficacy of Elastodontic Devices vs. Clear Aligners in Lower Intercanine Distance Changes Assessed by Computer-Aided Evaluation

Eleonora Ortu ^{1,*}, Davide Pietropaoli ¹ , Samuele Cova ², Mario Giannoni ¹ and Annalisa Monaco ¹

¹ Dipartimento di Medicina Clinica, Scienze della Salute e Dell'Ambiente, University of L'Aquila, P.le Salvatore Tommasi, 67100 L'Aquila, Italy

² Independent Researcher, 38023 Trento, Italy

* Correspondence: eleortu@gmail.com; Tel.: +39-0862434974

Abstract: Background: This pilot study aimed to verify the efficacy of two orthodontic appliances in relation to changes in the lower intercanine distance in growing patients. Methods: Twenty patients aged 10–16 years were enrolled in the study and separated into test and control groups. The test group included 10 patients (5 males, 5 females; mean age, 10.4 ± 1.57 years) who were treated with an elastodontic device. The control group included 10 patients (5 males, 5 females; mean age 10.8 ± 1.53 years) who were treated with clear aligners. The two groups exhibited the same orthodontic features. The orthodontic criteria were: skeletal class I relationship, molar class I relationship, and presence of lower crowding. Patients were evaluated as having mild or moderate crowding according to the Daniels and Richmond index. The lower intercanine distance was evaluated at three timepoints via intraoral scans: T0 (before starting therapy), T1 (after six months), and T2 (after 1 year). Data were analyzed using a nonparametric approach via the Wilcoxon signed-rank test. Results: There was no statistically significant difference between the two groups at T0, T1, or T2 ($p < 0.05$). Conclusions: elastodontic devices and clear aligners can successfully help the orthodontist conduct lower arch expansion treatment. These appliances are comfortable to wear, simple to clean every day, and reduce the number of dentist appointments. Finally, but not of least importance, these devices have allowed dentists to continue orthodontic treatments during the lockdowns of the COVID-19 pandemic.

Keywords: orthodontics; elastodontic device; clear aligners; dental crowding



Citation: Ortu, E.; Pietropaoli, D.; Cova, S.; Giannoni, M.; Monaco, A. Efficacy of Elastodontic Devices vs. Clear Aligners in Lower Intercanine Distance Changes Assessed by Computer-Aided Evaluation. *Oral* **2023**, *3*, 31–37. <https://doi.org/10.3390/oral3010003>

Academic Editor: Riccardo Nucera

Received: 21 November 2022

Revised: 7 January 2023

Accepted: 8 January 2023

Published: 15 January 2023



Copyright: © 2023 by the authors. Licensee MDPI, Basel, Switzerland. This article is an open access article distributed under the terms and conditions of the Creative Commons Attribution (CC BY) license (<https://creativecommons.org/licenses/by/4.0/>).

1. Introduction

One of the most frequent occurrences of malocclusion in Caucasian subjects seems to be dental lower crowding. The Third National Health and Nutrition Examination Survey of 1988–1994 (NHANES III) reported data from occlusal examinations performed on 7000 individuals between 8 and 50 years old. Data collected during the primary half of the survey showed that 21.9% of the population had a zero mandibular incisor irregularity (II) index; approximately 30% had clinically significant irregularity, and 15% had severe irregularity. Finally, the NHANES III survey showed that the mandibular II index value increased with age, from 1.6 mm between age 8 and 11 years, to 2.5 mm between 12 and 17 years, then to 3.0 mm between 18 and 50 years. Longitudinal studies have also shown that the incisors become more crowded after the permanent dentition is completely erupted [1]. These orthodontic defects may or may not be associated with skeletal malocclusions causing aesthetic and periodontal issues in patients. The etiological causes remain uncertain; however, early treatment of mixed dentition is strongly recommended [2]. There are many devices on the market designed to treat this type of defect, even though more and more patients and dentists now prefer to use elastodontic devices and clear aligners.

The term ‘elastodontic’ refers to a specific type of interceptive/orthognatodontic treatment based on the use of removable elastomeric devices [3]. These devices are characterized

by their extreme simplicity in terms of their use by the patient, their safety, and their construction. Elastodontic devices allow the dentist to finalize the treatment and create a harmonious and natural smile obtained using comfortable and non-invasive appliances. The aim is to achieve balance in the oral cavity without creating problems in other areas of the body. All of this can be obtained by stimulating the patient to use their own strengths (tongue and chewing muscles) and enabling their natural growth and remodeling potential to solve the problem of malocclusion [4,5]. For this reason, it is also called an activator or equilibrator (EQ) device. In selecting the most suitable device for the individual patient, after taking alginate impressions and developing cast stone models, the orthodontist uses an appropriate ruler to measure the distance between the palatal cusps of the first upper bicuspids (or the first upper deciduous molars) and will then choose the correct size. Three different materials are available based on hardness: white in natural rubber (soft), and orange or mint in elastomeric resin (medium and hard, respectively). The patient inserts his or her teeth in the upper and lower splint fittings as shown in Figure 1. This device is functionalized through soft elastic forces, led by muscle energy, by biting into it. The activator is worn all night and for 1 h during the day [6].

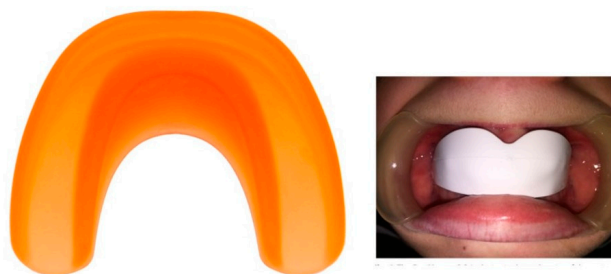

Figure 1. The Equilibrator Eptamed C3P orange and the Equilibrator C3P white in the oral cavity of the patient.

On the other hand, the clear aligners allow the best clinical results to be reached while maintaining the aesthetics for the individual subject. The aligner grants the control of 3D movements by holding all teeth on its surfaces (vestibular, palatal-lingual, and occlusal), and by applying proper forces through attachments of different shapes and sizes, and other specific features. One of the limitations of this technique is the impossibility of evaluating the neuromuscular approach in the both diagnostic phase and during orthodontic therapy [7].

The purpose of this study was to verify the clinical changes in the lower intercanine distance in growing patients using these two types of devices (EQ Series CP [Eptamed] versus Invisalign). The null hypothesis of this study was that there are no differences between the test and control groups in terms of lower expansion.

The authors of this study compared dental records before treatment, after 6 months, and after 12 months. The results are expected to provide guidelines on the most suitable devices for use in orthodontic practice.

2. Material and Methods

Study Sample

This study was carried out in accordance with the fundamental principles of the Declaration of Helsinki. It was approved before commencement by the Ethics Committee of the University of L'Aquila, Italy (no. 16137/2016). Sixty patients aged between 10–16 years were clinically examined at the Dental Clinic of the University of L'Aquila, Italy. The same clinician performed all examinations. Examinations included the acquisition of dental panoramic radiographs according to European guidelines on radiation protection in dental radiology, extraoral and intraoral photographs, and alginate impressions of both dental arches. Based on these data, the orthodontist created a treatment plan personalized to each patient, following application of the Index of Orthodontic Treatment Needs (IOTN)

described by Brook and Shaw and according to the Index of Complexity, Outcome and Need (Daniels and Richmond, 2000), which were used for measuring crowding [8,9]. The following exclusion criteria were applied: IOTN index > 4; presence of epilepsy, systemic disease, TMD, or periodontal disease; and/or lack of written informed consent from a parent or legal guardian. Inclusion criteria were: skeletal class I relationship, molar class I relationship, the presence of lower permanent incisors and canines, and the presence of lower crowding (mild or moderate). All of the patients (both in the test and control groups) were treated for arch expansion without IPR and rotation of the teeth.

Ultimately, 20 patients aged 10–16 years were enrolled in the study, and separated into test and control groups. The test group included 10 patients (5 males, 5 females; mean age, 10.4 ± 1.57 years), who were treated with the elastodontic device (EQ Series CP by Eptamed). The control group included 10 patients (5 males, 5 females; mean age 10.8 ± 1.53 years), who were treated with clear aligners. The two groups exhibited the same orthodontic features (Figure S1). The distance between the lower canines was evaluated at three timepoints: T0 (before starting therapy), T1 (after six months), and T2 (after 1 year). Scans of the dental arches of the two groups were taken by the same orthodontist (AM) at T0, T1, and T2. The variable of the study was the distance between the lower canines, which was evaluated using a virtual digital technique via Itero Intraoral Scan software [10]. To the best of our knowledge, this is the very first observation of a comparison between Eptamed and Invisalign devices, thus no preliminary data were available for the sample size calculation. Variables were analyzed using a nonparametric approach via the Wilcoxon signed-rank test, and we hypothesized that there would be no statistically significant difference between the two groups.

3. Experimental Settings

Each patient in the test group received a medium hardness, orange elastodontic CP model device that was suitable for their dentition phase [6]. This device has a similar shape to a mouthguard, and embraces both dental arches, reaching distally to cover the last molars present in the arch. There are several sizes, based on the distance between the palatal cusps of the first premolars or deciduous molars. The patient inserts the device's upper and lower splints over their teeth. The device is activated by biting down on it, activating soft elastic forces generated by muscle energy, and it is mostly worn overnight. It is innovative in its structure because it stimulates maxillary growth, and as a consequence of the muscle movements, it elicits tissue development, enabling the patient to gain a suitable chewing function. The patient, biting down onto this elastomeric tray, balances the tension of the sphenobasilar synchondrosis compression, an outcome based on osteopathic medicine and philosophy [4,6]. This device acts to rehabilitate both the tongue and nasal respiration, allows the alignment of the teeth, and relaxes the stomatognathic and postural muscles (Figure 1). Patients in the test group were instructed to wear the device at night. Monthly checks were performed to assess the level of alignment, and more importantly, to evaluate the requirement for any modifications to be made to the device. In fact, the activator was frequently modified by the orthodontist to allow full integration into the oral cavity. In addition, the device was substituted every 4 months, after evaluating the growth of the subject, to adapt it to the size of the arches. A maneuver to effect manual widening of the device was performed during this 4-month period as required; this serves to restore the initial elastic memory.

Subjects enrolled in the control group were asked to change the pre-formed clear aligners that had been previously delivered to them every week. They were instructed that these aligners should be worn as much as possible throughout the day and should be removed only to eat. In the subjects of the control group, the upper arch was also treated with clear aligners. The orthodontist checked all patients in the test and control groups every 30 days to evaluate the need for any modifications to optimize the execution of the device.

All patients were cooperative. No enrolled patients withdrew from therapy.

4. Results

Due to the small sample size, data were analyzed using a nonparametric approach via the Wilcoxon signed rank test. Statistical significance was set at $p < 0.05$. To determine whether any differences in the lower canine distance before and after treatment were related to sex and/or physiologic growth differences between the two groups, the differences in the lower canine values were evaluated for age and sex through the Wilcoxon test. There were no statistically significant differences between the test and control groups at T0, T1, or T2. Thus, the results were dependent only on the type of device used and were not related to sex or age. The two devices appeared to be equally effective at T1 and T2 in increasing the distance between the lower canines, as shown in Table 1 and Figure 2, and so the authors confirmed the initial hypothesis on the comparative usefulness of the two devices.

Table 1. Results (mean and SD) for the two groups. Distances between the lower canines at T0, T1, T2 are expressed in mm. There is no statistically significant difference in the values of the two groups related to sex or age at T1 and T2.

	Stratified by Treatment		<i>p</i>
	Eptamed	Invisalign	
<i>n</i>	10	10	
sex = M (%)	5 (50.0)	5 (50.0)	1.000
age (mean (SD))	10.40 (1.58)	10.80 (1.62)	0.583
T0 (mean (SD))	26.75 (1.58)	26.39 (1.47)	0.605
T1 (mean (SD))	27.14 (1.45)	27.19 (1.05)	0.931
T2 (mean (SD))	27.08 (1.44)	27.11 (1.04)	0.958

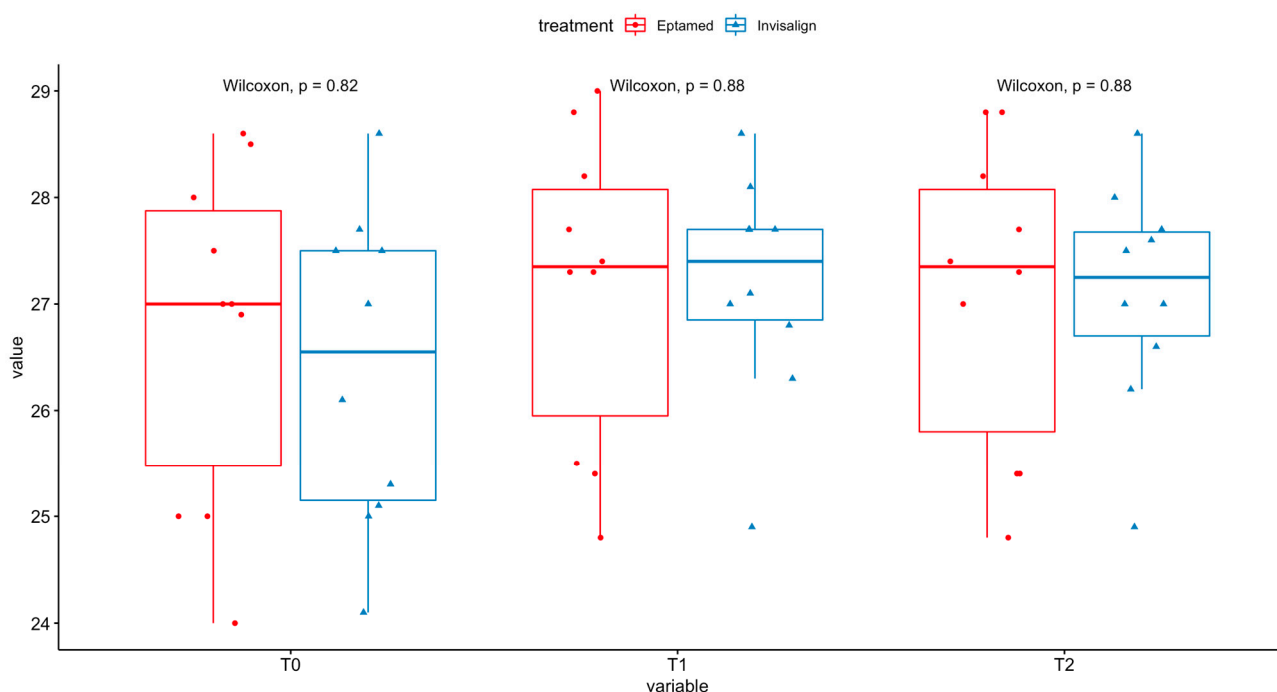


Figure 2. Bar plot of lower intercanine distance values stratified by timing according to group “Eptamed” vs. group “Invisalign”. The two groups exhibited the same results; the values of *p* were 0.82 at T0 and 0.88 at both T1 and T2.

5. Discussion

From the results of this study, it emerged that the two devices analyzed displayed no statistically significant differences in terms of arch expansion results measured by

intercanine distance, as shown in Table 1 and Figure 2. More precisely, the two devices analyzed seem to work in the same way by expanding the lower arch and thus increasing the intercanine distance. There were improvements demonstrated in both groups at times T1 and T2. Clear aligners are an aesthetic and comfortable option for orthodontic treatment and have gained immense popularity over the last decade. These devices' main focus is to provide a natural and ergonomic treatment experience; to facilitate oral hygiene; to cause less pain compared to fixed orthodontic procedures; to reduce the number and duration of appointments; and to require fewer emergency visits. Most of the time, unfortunately, the cost of the therapy does not allow the dentist to choose the aligners over the most common options [6,11].

In recent scientific studies, authors who have studied the effectiveness of clear aligners have shown differing results. As analyzed in an article by Caruso et al., clear aligners have a biomechanical action to control the inclination of the incisors, which could be attributed to their structure, which surrounds the tooth crown surface [12]. Kassas et al. reported that the clear aligner system is effective in leveling and aligning arches in mild and moderate cases, and also in correcting buccolingual inclinations; however, it is not sufficient in providing an ideal occlusal contact with the posterior teeth [13]. Their deterioration is caused by the thickness of the aligners, which interferes with the settling of the occlusal plane [13]. Yıldırım et al. investigated whether the effectiveness of the teeth movements was due to the use of clear aligner devices. In their study, the retrusion of the mandibular central incisors was considered to be the most accurate single-tooth movement, but long-term stability studies still need to be presented on this matter [14]. It might also be noted that elastodontic devices are valid aids for early treatment regimes, reconditioning the natural growth forces of the neuro-musculoskeletal system to correct malocclusions. Recent studies demonstrate that these devices are optimal for the entire stomatognathic system, and that the absence of indentations allows simultaneous involvement of both dental arches, with the repositioning having multidimensional orthopedic effects to give the teeth the freedom to find their position without any pressure [3]. Furthermore, these devices can correct functional problems in the soft tissues, such as a lingual malposition, a centripetal thrust of the lips and cheeks, and oral breathing. They improve skeletal and dentoalveolar malocclusions and restore normal muscular activities, rebalancing the perioral, oral, and lingual musculature. In addition, they can be used in the reduction of overjet and overbite, and to reduce relapse over time [3]. In a study conducted by Ortu et al., electromyographic analysis of patients wearing elastodontic devices demonstrated a greater degree of muscle relaxation in those with mandibular retrusion, which was attributed to the fact that these devices are both simple to use and comfortable [15]. In a study by Marra P., elastodontic devices were successfully used to treat the issue of tongue thrust in open bite malocclusions. They eliminate functional disorders of the stomatognathic system and exert three-dimensional effects within the oral cavity, improving breathing, swallowing, and postural abnormalities [16]. However, this study is limited by its small sample size and short follow-up interval. It might be useful to repeat this study with a larger, and possibly more homogeneous, cohort.

6. Conclusions

During this study the authors showed how elastodontic devices and clear aligners may be both utilized to treat and expand the lower arch, and to enhance the final orthodontic treatment. Both techniques analyzed here improved the degree of lower dental arch crowding during the orthodontic therapies. These methodologies showed clinical effectiveness to achieve therapeutic targets with a low impact on the patient's attitude towards compliance. Classic orthodontic techniques, in which often painful braces, arches, and elastics are used, are slowly disappearing, to make way for new methods such as elastodontic devices and clear aligners. Modern orthodontics, which has a very wide scope, involves the use of devices that are easy to handle and clean, give excellent aesthetic and functional results, and do not cause TMD or long-term relapse. There are still few scientific articles in the literature

demonstrating this, but given the speed with which these techniques are spreading among orthodontists, soon the literature will show even more encouraging results.

Supplementary Materials: The following supporting information can be downloaded at: <https://www.mdpi.com/article/10.3390/oral3010003/s1>, Figure S1: *Study flowchart*.

Author Contributions: A.M. performed treatments; S.C. collected the data; E.O. and A.M. conceived the ideas and revised the manuscript; D.P. contributed to data interpretation, statistical analyses, and edited the manuscript; M.G. contributed to the research plan and manuscript discussion. All authors participated in the writing of the manuscript. All authors have read and agreed to the published version of the manuscript.

Funding: This research received no external funding.

Institutional Review Board Statement: Not applicable.

Informed Consent Statement: This study was approved by the Ethics Committee of the University of L'Aquila (no. 16137/2016). Written informed consent was obtained from all parents or legal guardians of the subjects involved in the study.

Data Availability Statement: Not applicable.

Acknowledgments: The authors acknowledge all of the staff of the Dental Clinic of the University of L'Aquila.

Conflicts of Interest: The authors declare no conflict of interest.

References

1. Bishara, S.E.; Treder, J.E.; Jakobsen, J.R. Facial and dental changes in adulthood. *Am. J. Orthod. Dentofac. Orthop.* **1994**, *106*, 175–186. [[CrossRef](#)] [[PubMed](#)]
2. Rapeepattana, S.; Thearomtree, A.; Suntornlohanakul, S. Etiology of Malocclusion and Dominant Orthodontic Problems in Mixed Dentition: A Cross-sectional Study in a Group of Thai Children Aged 8-9 Years. *J. Int. Soc. Prev. Community Dent.* **2019**, *9*, 383–389. [[CrossRef](#)] [[PubMed](#)]
3. Inchingolo, A.D.; Patano, A.; Coloccia, G.; Ceci, S.; Inchingolo, A.M.; Marinelli, G.; Malcangi, G.; Montenegro, V.; Laudadio, C.; Pede, C.D.; et al. The Efficacy of a New AMCOP[®] Elastodontic Protocol for Orthodontic Interceptive Treatment: A Case Series and Literature Overview. *Int. J. Environ. Res. Public Health* **2022**, *19*, 988. [[CrossRef](#)] [[PubMed](#)]
4. Ortu, E.; Pietropaoli, D.; Cova, S.; Marci, M.C.; Monaco, A. Efficacy of elastodontic devices in overjet and overbite reduction assessed by computer-aid evaluation. *BMC Oral Health* **2021**, *21*, 269. [[CrossRef](#)] [[PubMed](#)]
5. Ravera, S.; Rollet, D.; Cugliari, G.; Deregibus, A.; Castroflorio, T. Interceptive treatment effects of EF preformed appliance in pre-pubertal and pubertal skeletal Class II growing patients: A retrospective controlled study. *Eur. J. Paediatr. Dent.* **2020**, *21*, 123–128. [[CrossRef](#)] [[PubMed](#)]
6. Aprile, G.; Ortu, E.; Cattaneo, R.; Pietropaoli, D.; Giannoni, M.; Monaco, A. Orthodontic management by functional activator treatment: A case report. *J. Med. Case Rep.* **2017**, *11*, 336. [[CrossRef](#)] [[PubMed](#)]
7. Caruso, S.; Nota, A.; Ehsani, S.; Maddalone, E.; Ojima, K.; Tecco, S. Impact of molar teeth distalization with clear aligners on occlusal vertical dimension: A retrospective study. *BMC Oral Health* **2019**, *19*, 182. [[CrossRef](#)] [[PubMed](#)]
8. Brook, P.H.; Shaw, W.C. The development of an index of orthodontic treatment priority. *Eur. J. Orthod.* **1989**, *11*, 309–320. [[CrossRef](#)] [[PubMed](#)]
9. Daniels, C.; Richmond, S. The development of the index of complexity, outcome and need (ICON). *J. Orthod.* **2000**, *27*, 149–162. [[CrossRef](#)] [[PubMed](#)]
10. Shibasaki, W.M.M.; da Silva, L.H.; Fuziy, A.; Trivino, T.; Costa, A.L.F.; Nahas-Scocate, A.C.R. Evaluation of lower anterior dental changes in patients treated with self-ligating brackets. *J. Oral Biol. Craniofac. Res.* **2019**, *9*, 183–186. [[CrossRef](#)] [[PubMed](#)]
11. Boyd, K.; Saccomanno, S.; Lewis, C.J.; Coceani Paskay, L.; Quinzi, V.; Marzo, G. Myofunctional therapy. Part 1: Culture, industrialisation and the shrinking human face. *Eur. J. Paediatr. Dent.* **2021**, *22*, 80–81. [[CrossRef](#)] [[PubMed](#)]
12. Caruso, S.; Nota, A.; Caruso, S.; Severino, M.; Gatto, R.; Meuli, S.; Mattei, A.; Tecco, S. Mandibular advancement with clear aligners in the treatment of skeletal Class II. A retrospective controlled study. *Eur. J. Paediatr. Dent.* **2021**, *22*, 26–30. [[CrossRef](#)] [[PubMed](#)]
13. Kassas, W.; Al-Jewair, T.; Preston, C.B.; Tabbaa, S. Assessment of Invisalign treatment outcomes using the ABO Model Grading System. *J. World Fed. Orthod.* **2013**, *2*, e61–e64. [[CrossRef](#)]
14. Yıldırım, A. A Prospective Study to Determine the Efficiency of Clear Aligner Appliance. Ph.D. Thesis., Istanbul University Institute of Health Sciences Orthodontics Department, Istanbul, Turkey, 2013.

15. Ortu, E.; Barrucci, G.; Aprile, G.; Guerrini, L.; Pietropaoli, D.; Monaco, A. Electromyographic evaluation during orthodontic therapy: Comparison of two elastodontic devices. *J. Biol. Regul. Homeost. Agents* **2020**, *34*, 1935–1939. [[CrossRef](#)] [[PubMed](#)]
16. Marra, P.M.; Fiorillo, L.; Cervino, G.; Cardarelli, F.; Ciccio, M.; Laino, L. Elastodontic treatment with oral bio-activators in young children. *Minerva Dent. Oral Sci.* **2022**, *71*, 270–276. [[CrossRef](#)] [[PubMed](#)]

Disclaimer/Publisher’s Note: The statements, opinions and data contained in all publications are solely those of the individual author(s) and contributor(s) and not of MDPI and/or the editor(s). MDPI and/or the editor(s) disclaim responsibility for any injury to people or property resulting from any ideas, methods, instructions or products referred to in the content.